

## OVUM RETENTION IN THE HUMAN

IAN CRAFT, F.R.C.S., M.R.C.O.G.\*  
KAREN SHELTON, B.Sc.(HON.)  
JOHN YOVICH, M.R.C.O.G.  
DAVID SMITH, M.R.C.O.G., M.AUST.C.O.G.

*Academic Department of Obstetrics and Gynaecology, Royal Free Hospital,  
London, United Kingdom*

*Two cases of ovum retention occurring in postovulatory follicles are described. The ova were recovered at laparoscopy by aspiration of decompressed ovulatory follicles, one during a natural cycle and the other following a programmed clomiphene/human chorionic gonadotropin cycle. Each patient had a normal luteal phase with an increased progesterone level indicative of ovulation. The implications of these findings and their relevance to human fertility studies are discussed.  
Fertil Steril 34:537, 1980*

One-third of infertile women seeking advice about infertility have ovulatory defects,<sup>1</sup> that is, a failure of the process whereby a mature secondary oocyte is discharged from the ovary. Ovulation follows synchronized and balanced gonadotropic stimulation. Gonadotropins promote follicular growth and differentiation of the follicular cells, with characteristic steroid production from a responsive Graafian follicle and subsequent post-ovulatory corpus luteum. Coordination of the various hormonal events in the hypothalamic-pituitary-ovarian axis has been recently reviewed.<sup>2-4</sup> Gonadotropins, clomiphene citrate, and bromocriptine can be effective in treating anovulatory infertility. However, there is a marked difference between ovulation and pregnancy rates. In one study, clomiphene induced ovulation in 66.5% of a large series but the pregnancy rate was only 25%.<sup>5</sup> Taymor<sup>6</sup> reported a 72% ovulation rate and a 54% conception rate with gonadotropin therapy. There is no adequate explanation for this discrepancy, but ovum retention within a follicle which has discharged the remainder of its follicular contents

may be associated with various parameters consistent with presumed normal ovulation, i.e., a biphasic basal temperature chart, increased urinary pregnanediol and serum progesterone levels, cervical mucus and vaginal cytologic changes, secretory endometrium, and the development of a corpus luteum; therefore, retention of the ovum might explain some of the cases in which ovulation apparently occurred but conception failed to take place.

We report the findings of retention of a preovulatory oocyte within a postovulatory follicle in each of two patients who subsequently exhibited features consistent with normal ovulation.

### METHODS

A research program and health service commitment involving ovum collection and in vitro fertilization with reimplantation for treatment cases is in operation following approval by the Ethical Committee. Ninety-five ovum collections have been performed. Fifty were carried out in infertile women with inoperable tubal damage and forty-five in fertile women at the time of voluntary sterilization. Preovulatory oocytes were aspirated from maturing follicles at laparoscopy using the techniques described by Steptoe and Edwards.<sup>7</sup> Some patients were managed with a programmed

Received May 27, 1980; revised August 15, 1980; accepted August 20, 1980.

\*Reprint requests: Professor I. Craft, Academic Department of Obstetrics and Gynaecology, Royal Free Hospital, Pond Street, London NW3 2QG, England.

cycle of clomiphene citrate administration during the early follicular phase and human chorionic gonadotropin (hCG) on or about day 11 of the cycle. Ova were aspirated 32 to 35 hours after the hCG injection, since ovulation usually begins approximately 37 hours after the triggering dose of hCG.<sup>8</sup> Apart from the anesthetic agents, no drugs were used and in particular no support was given to the luteal phase of the cycle. Some patients requiring embryo reimplantation underwent ovum collection during a natural cycle. For these patients, frequent estimations of urinary luteinizing hormone (LH) were made, and aspiration was planned for a time within 24 hours of the beginning of the luteal surge.<sup>9</sup>

The LH titers on urine were undertaken using Hi-Gonavis (Mochida Pharmaceutical Co. Ltd., Tokyo, Japan), which detects levels as low as 12.5 IU/liter in undiluted urine. The assay is based on the principle of preventing hemagglutination of anti-hCG-sensitized erythrocytes by the prior reaction of urinary LH with anti-hCG serum. The test is cross-reactive with hCG (from 5 IU/liter).

Progesterone assays were performed by radioimmunoassay after ether extraction of the serum and subsequent dextran-coated charcoal separation of free and bound hormone. The normal midluteal range for the endocrine laboratory in this hospital is 30 to 75 nmoles/liter.

## RESULTS

*Case 1—Natural Cycle.* This 35-year-old woman was admitted for treatment of infertility by extracorporeal fertilization. She had a history of a first-trimester therapeutic abortion followed by bilateral salpingectomy for two separate ectopic pregnancies. All of the pregnancies were attributed to her current partner. She had a regular menstrual pattern (27- to 29-day cycle with a 5-day flow), a biphasic basal body temperature chart, and normal serum levels of prolactin and midluteal phase progesterone. Her partner's semen exhibited mild to moderate oligospermia with volumes of 3 to 4 ml and counts of 14 to 28 million/ml with a motility of 50% at 1 hour.

Ovum collection was planned for a natural cycle. Following menstruation on April 3, 1979, serial ultrasound tracking of the ovaries was performed during the follicular phase with urinary LH determinations on 3-hour specimens from day 10. On day 12 of the cycle, rising titers of LH were detected with a peak at about 5 A.M. Fig. 1. Eight

hours later a transonic area approximately 2.5 cm in diameter was noted in the left ovary Fig. 2; laparoscopy was planned 16 hours after the LH peak but unfortunately was delayed 2 hours because of an emergency operation. At laparoscopy ovulation was noted to have already occurred, there being a completely collapsed follicle on the inferior surface of the left ovary. Serosanguineous fluid (approximately 20 ml) was noted in the pouch of Douglas. An aspiration needle was inserted into the empty follicle via its punctum site and a small amount of bloody aspirate was obtained. We were surprised to find a preovulatory oocyte surrounded by its corona radiata and held in a loose cumulus mass in the specimen after blood in the aspirate had been dispersed using heparinized, modified Tyrode's solution. The fluid from the pouch of Douglas was also aspirated, and clumps of follicular cells and epithelial debris usually seen in mature follicles were found but there was no ovum.

The recovered oocyte was treated in the routine manner for extracorporeal fertilization and culture. It was a fully mature ovum with its polar body clearly visible after cumulus dispersion. However, it failed to be fertilized and this failure was attributed to the poor quality of spermatozoa, which could not survive beyond 12 hours in the

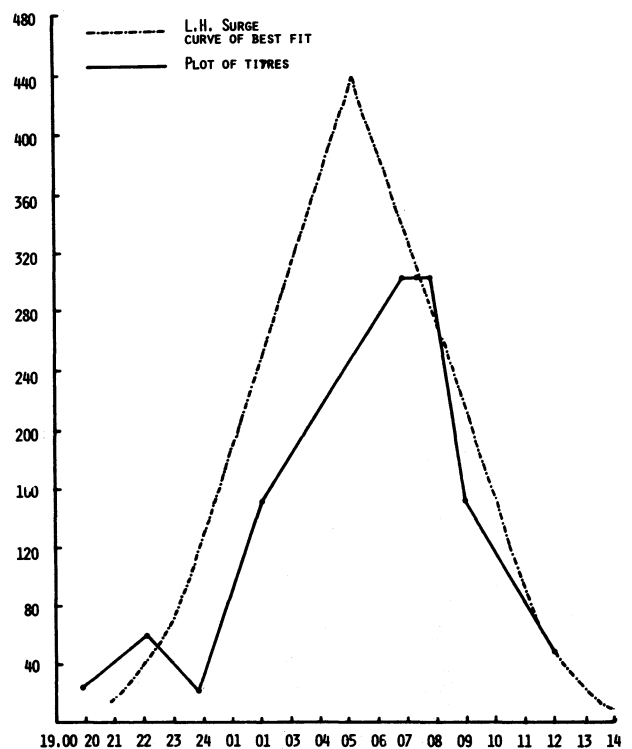


FIG. 1. Urinary LH estimations using Hi-Gonavis (case 1).

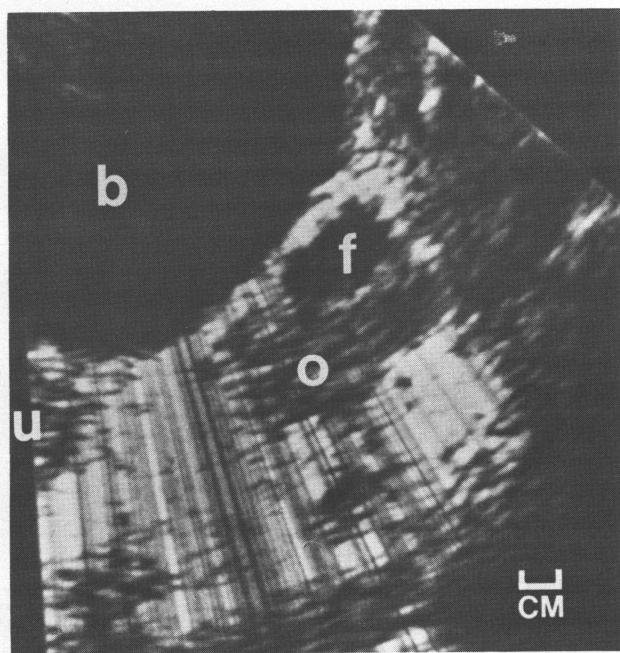


FIG. 2. Pelvic ultrasound (case 1). *b*, Bladder; *u*, uterus; *o*, left ovary; *f*, follicle.

medium. In successful cases, fertilized ova are surrounded by active spermatozoa for up to 72 hours in our *in vitro* system.

The patient's cycle and basal body temperature chart (Fig. 3) were normal. A serum progesterone value 7 days after ovum collection was 34 nmoles/liter. Ultrasound performed 2 days after laparoscopy demonstrated that there was no longer a large follicle in the left ovary. The appearances had changed to those of a moderately transonic area approximately 1.5 cm in diameter with a diffuse, irregular margin consistent with the presence of a corpus luteum.

**Case 2—Programmed Cycle.** This 40-year-old woman was admitted for laparoscopic clip sterilization. She had two teenage children and a history of three spontaneous abortions. Her menstrual pattern was regular (28-day cycle with a 5-day flow). She had voluntarily agreed to donate ova for laboratory study and had received clomiphene citrate, 100 mg daily, on days 5 to 9 of the cycle. hCG, 10,000 IU, was given at 3 A.M. on day 13 of this cycle since we were unable to admit the patient 2 days earlier as desired. At laparoscopy 34 hours after hCG administration, a Hulka-Clemens clip sterilization procedure was performed and two follicles, each 1 cm in diameter and containing light straw-colored fluid, were aspirated from the right ovary. A similar follicle 1.5 cm in diameter was aspirated from the left

ovary, which also contained a ruptured 1.5-cm follicle with a small clot at the punctum site. An aspirating needle was then inserted in the punctum site and a small amount of blood-stained gelatinous fluid was recovered which subsequently revealed a mature preovulatory oocyte in loose cumulus, as did two of the three intact follicles. All three ova were mature, since polar bodies were present and each ovum subsequently was fertilized with the same donor sperm and reached the eight-cell stage before growth was terminated. A fourth oocyte (from the right ovary) was immature, surrounded by tight cumulus, and failed to fertilize.

Seven days after laparoscopy the serum progesterone level was 87 nmoles/liter and menstruation occurred 15 days after collection of ova. Uterine curettage performed at the completion of laparoscopy was reported as showing early secretory phase endometrium.

#### DISCUSSION

Failure of ovum release has been well described in several animals (e.g., rats,<sup>10, 11</sup> rabbits<sup>12, 13</sup> and monkeys.<sup>13-15</sup> Its documented study has shed light on the role of prostaglandins during the ovulatory process. In 1972<sup>10</sup> it was reported that ovum release in rats could be inhibited *in vivo* in both spontaneous and gonadotropin-stimulated cycles using indomethacin. This action was attributed to the ability of indomethacin to inhibit prostaglandin biosynthesis.

Additional studies have clarified that ovulation is a sequential process comprising several distinct events which may have independent control mechanisms. These events include (1) the process of ovum maturation to effect resumption of meiotic division (reaching metaphase II at ovum release in the human); (2) the development of characteristic steroidogenesis activity and subsequent luteinization of the follicle, which begins prior to ovulation

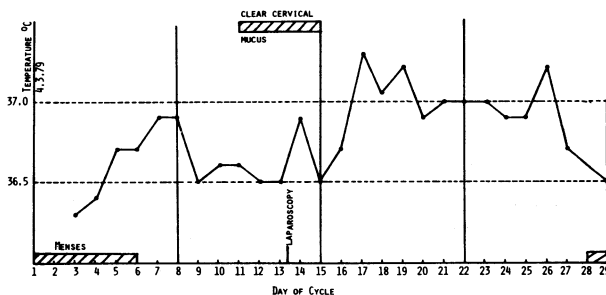


FIG. 3. Basal body temperature chart (case 1).

and continues after ovum discharge with the gradual conversion of the follicle into a mature corpus luteum; and (3) the undoubtedly complex but precisely timed process of follicle rupture with the release of fluid and the mature ovum. The trigger for each of these events is clearly the LH surge. Most studies<sup>11-15</sup> have indicated that both prostaglandin E<sub>2</sub> (PGE<sub>2</sub>) and LH stimulate the adenylate cyclase system leading to ovum maturation, steroidogenesis, and luteinization. However, as a recent review pointed out,<sup>16</sup> the precise interplay among LH, PGE<sub>2</sub>, adenylate cyclase activity, and cyclic adenosine 3':5'-monophosphate response is complex and there appears to be interspecies variation. Follicle rupture appears more dependent upon PGF<sub>2α</sub>.

In rats,<sup>10</sup> rabbits,<sup>12, 13</sup> and monkeys<sup>13-15</sup> the prevention of PGF<sub>2α</sub> synthesis by indomethacin or PGF<sub>2α</sub> antiserum may lead to ovum retention within a corpus luteum which is histologically normal and which continues to produce progesterone in normal amounts. Again the precise action and importance of the role of a particular prostaglandin in different species<sup>16, 17</sup> leaves an unclear picture requiring specific study for clarification in humans. The actual mechanism of ovum release is currently contested between the two major theories of local enzyme formation leading to dissolution of the wall at the stigma<sup>17</sup> and prostaglandin-induced ovarian contractility.<sup>18</sup> Although it is no longer believed that rising intrafollicular pressure occurs within the developing follicle, there is some evidence that preovulatory pressure increases do occur,<sup>19</sup> possibly secondary to intraovarian contractions.

Human investigation has been minimal, and we have not found previous reports of ovum retention. We believe that the above cases are the first two documented examples in women. The first patient underwent ovum collection for extracorporeal fertilization, and this collection was one of a series of 50 scheduled for this purpose; most of these patients had programmed cycles, but a few ova have recently been collected during natural cycles. In this group, follicle rupture was noted on two occasions. A preovulatory oocyte was recovered from the pouch of Douglas in the other instance. Subsequently, two mature ova were collected from case 1 and successfully fertilized with donor sperm.

The second example of ovum retention was noted in a series of 45 ovum collections in women undergoing sterilization. In this series three women were discovered to have ruptured follicles at laparoscopy. Our observation that ovum reten-

tion had occurred in two of five postovulatory follicles warrants further specific study. The only documented human investigation<sup>20</sup> concerned a series of five women given aspirin and timed to undergo sterilization during the luteal phase of the cycle. There was no incidence of "entrapped" ova on histologic sections of the corpora lutea. Normal signs of ovulation were found.

Our findings of normal midluteal progesterone levels, normal biphasic basal body temperature charts, and normal luteal phase lengths demonstrate that clinicians are still unable to define precisely whether or not normal ovulation—with ovum release—has occurred. This of course has significant implications regarding the assessment of any infertility management studies.

We suggest that the retention of a mature ovum in the follicle cavity after discharge of the follicular contents be termed ovum *retention*, in contrast to ovum entrapment which occurs in periovarian adhesions subsequent to normal ovulation, and to that situation described in animals where the follicle presumably fails to rupture and release any of its contents.

*Acknowledgments.* We are grateful to Richard Wolf GMBH, UK Ltd., Mitcham, Surrey, and to E. Leitz (Instruments) Ltd., Luton, Bedfordshire, United Kingdom, for the loan of equipment to support our studies; to the Endocrine Laboratory, Department of Chemical Pathology, Royal Free Hospital, for the progesterone assays; and to Jessica Parvin for secretarial assistance.

#### REFERENCES

1. Lunenfeld B, Insler V: Classification of anovulatory states. In *Infertility: Diagnosis and Treatment of Functional Infertility*. Berlin, Grosse Verlag, 1978, p 12
2. McNeilly AS: Effects of lactation on fertility. *Br Med Bull* 2:151, 1979
3. Fink G: Neuroendocrine control of gonadotrophin secretion. *Br Med Bull* 2:155, 1979
4. Henderson KM: Gonadotrophin regulation of ovarian activity. *Br Med Bull* 2:161, 1979
5. Murray M, Osmond-Clark F: Pregnancy results following treatment with clomiphene citrate. *Br J Obstet Gynaecol* 78:1108, 1971
6. Taymor ML: Evaluation of anovulatory cycles and induction of ovulation. *Clin Obstet Gynaecol* 1:145, 1979
7. Steptoe PC, Edwards RG: Laparoscopic recovery of preovulatory human oocytes after priming of ovaries with gonadotrophins. *Lancet* 1:683, 1970
8. Edwards RG, Steptoe PC: Induction of follicular growth, ovulation and luteinization in the human ovary. *J Reprod Fertil [Suppl]* 22:121, 1975
9. Steptoe PC, Edwards RG: Pregnancies following implantation of human embryos grown in culture. Unpublished data presented at Scientific Meeting, Royal College of Obstetricians and Gynaecologists, London, January 26, 1979

10. Armstrong DT, Grinwich DL: Blockade of spontaneous and LH-induced ovulation in rats by indomethacin, an inhibitor of prostaglandin biosynthesis. *Prostaglandins* 1:21, 1972
11. Tsafirri A, Lindner HR, Zor U, Lamprecht SA: Physiological role of prostaglandins in the induction of ovulation. *Prostaglandins* 2:1, 1972
12. Armstrong DT, Grinwich DL, Moon YS, Zamecnik J: Inhibition of ovulation in rabbits by intrafollicular injection of indomethacin and prostaglandin F antiserum. *Life Sci* 14:129, 1974
13. Hamada Y, Wright KH, Wallach EE: In vitro reversal of indomethacin-blocked ovulation by prostaglandin F<sub>2α</sub>. *Fertil Steril* 30:702, 1978
14. Wallach EE, Bronson R, Hamada Y, Wright KH, Stevens VC: Effectiveness of prostaglandin F<sub>2</sub> alpha in restoration of HMG-HCG induced ovulation in indomethacin-treated Rhesus monkeys. *Prostaglandins* 10:129, 1975
15. Maia H, Barbosa I, Coutinho EM: Inhibition of ovulation in marmoset monkeys by indomethacin. *Fertil Steril* 29:565, 1978
16. Karim SMM, Hillier K: Prostaglandins in the control of animal and human reproduction. *Br Med Bull* 35:173, 1979
17. Lemaire WJ, Marsh JM: Inter-relationships between prostaglandins, cyclic AMP and steroids in ovulation. *J Reprod Fertil [Suppl]* 22:53, 1975
18. Coutinho EM, Maia HS: The contractile response of the human uterus, fallopian tubes and ovary to prostaglandins in vivo. *Fertil Steril* 22:539, 1971
19. Coutinho EM, Maia HS, Schally AV: Changes in intra-ovarian pressure in woman following the administration of luteinizing hormone-releasing hormone (LHRL). *Int J Fertil* 19:89, 1974
20. Chaudhuri G, Elder MG: Lack of evidence of inhibition of ovulation by aspirin in women. *Prostaglandins* 11:727, 1976