

The Diagnostic Value of a Routine Genito-Urinary Ultrasound Examination for Men Attending an Infertility Clinic

Anne M Jequier¹, Neville Phillips² and John L Yovich^{1*}

¹PIVET Medical Centre, Leederville, Perth, Western Australia 6007, Australia

²Wembley Obstetric & Gynecological Ultrasound, Wembley, Perth, Western Australia 6014, Australia

*Corresponding author: John L Yovich MBBS MD FRCOG FRANZCOG CREI, PIVET Medical Centre, 166-168 Cambridge Street, Leederville, Perth, Western Australia 6007, Australia; E-mail: jlyovich@pivet.com.au

Rec date: Dec 03, 2013 Acc date: Dec 30, 2014 Pub date: Jan 5, 2015

Abstract

Introduction: This study examines the value of genito-urinary ultrasound examination in the evaluation of infertility in a group of 1203 men attending an infertility clinic over a period of 3 years. A genito-urinary ultrasound examination and a semen analysis were carried out on each of these men at or close to their first visit to the clinic.

Results: Of these 1203 men, 748 (62%) had a semen analysis that was classified normal while in the remaining 455 men the semen analysis showed subnormal parameters by WHO standards. A wide range of abnormalities were detected that included 5 cases of testicular cancer, 66 cases of testicular microlithiasis, 15 men with cystic ectasia of the rete testis and 52 men with lesions of the renal tract. Varicoceles were highly prevalent at 52% of men, although less than half (45% of men with varicoceles) showed subnormal semen profiles but 15% displayed ipsilateral testicular volumetric reduction ≥ 5 mls. Semen analysis showed a low positive predictive value PPV, with the ultrasound findings (43%).

Discussion: The prevalence of a large number of men with both cancer and possible pre-cancer in the form of testicular microlithiasis makes the use of ultrasound an important investigation in the evaluation of infertility in the male. However the lowish PPV of 71% implies that a more conservative approach than orchidectomy should be considered by Urologists managing such asymptomatic men. Many other lesions are also revealed, not readily detected by clinical examination and varicoceles are better categorized.

Conclusions: These findings support the application of a routine genito-urinary ultrasound examination as a useful investigation in the evaluation of the male partner presenting in the context of infertility.

Key words:

Genito-urinary ultrasound examination; Male infertility

Introduction

All too frequently, male infertility is defined solely in relation to a semen analysis. All too commonly, the male partner does not have a history taken and scant attention is given to identifying the underlying cause of that infertility [1]. It is now also realized that many of the changes seen in a semen analysis are entirely non-specific [2,3]. It has even been suggested that a semen analysis may one day become obsolete as a diagnostic test [4].

In an attempt to improve the diagnostic basis of treatment among infertile men, it became a group decision at PIVET Medical Centre that all men attending the infertility clinic be offered a genito-urinary ultrasound procedure in addition to clinical examination and semen analysis. A genito-urinary procedure was performed rather than the simpler testicular ultrasound due to the known relationship between renal lesions and some causes of male infertility including testicular maldescent [5] and varicoceles [6].

In this communication, the findings of a routine genito-urinary ultrasound examination are reported in all male partners attending an infertility clinic over a period of 3 years. The types of lesions demonstrated by the ultrasound examinations are described in this largely asymptomatic group.

Materials and Methods

Patients

A group of 1228 men agreed to combine investigations when they attended the infertility clinic at PIVET Medical Centre with their wives or female partners over the 3-year period 2008 to 2011. Regardless of symptoms or the knowledge of male or female fertility factors, each underwent a routine genital examination, a semen analysis and a genito-urinary ultrasound examination. These patients attended consecutively and included only those who completed the 3 studies (1203 men). During the 3-year period only 25 men did not complete the investigations and are completely excluded from the study report.

Semen analysis

All the men in this study underwent at least one semen analysis. This was carried out in accordance with the procedures laid out in the World Health Organization publication 'Laboratory Manual for the Examination of Spermatozoa and Sperm-Cervical Mucus interaction' [7] which designated the semen analysis criteria for most of the period under study. Based on these criteria, the semen was deemed to be either fertile (with normal parameters on any one semen sample) or subfertile (subnormal parameters on 2 or 3 samples).

The lesions detected by the genitourinary ultrasound examination

All ultrasound examinations were carried out by one of 2 experienced sonographers using a Phillips HD 1500 Sono CT machine (Philips Electronics NV, Netherlands). The renal tract was assessed by trans-abdominal scanning and a trans-vesical assessment was made of the prostate using a 3.75 convex array probe. The testes were examined using a 10 Mega-Hertz array transducer in both longitudinal and transverse sections. The epididymis on each side was also examined in both planes.

The presence of a varicocele was also sought on each side and was classified according to reversal of venous flow only on Valsalva manoeuvre with veins >2mms (Grade 1), varicocele without Valsalva but width < testis (Grade 2), varicocele width \geq testis (Grade 3) and varicocele width \geq X2 testis (Grade 4); matching the clinical feature known as “bag-of-worms” [8]. Testicular volumes were also measured.

Clinical examinations

All patients referred to PIVET Medical Centre received a clinic brochure which informed them that all infertility couples were required to attend together and that both partners would be examined as a routine, regardless of perceptions about which might be considered the “infertile” partner.

All men had height, weight and BMI checked along with blood pressure as a routine for all patients attending the Clinic. This was done by the clinic nurse and applied to both the man and his partner/wife. The fertility consultant, a gynaecologist, undertook the history-taking and examined each partner, regardless of the historical information. Men were examined standing after dropping trousers and underpants to the ankles. The genitalia were examined along with inguinal areas as well as thoracic and abdominal inspection for gynaecomastia and body hair distribution. Each testis was palpated and size estimated; lumps or swellings were described and varicoceles judged according to Valsalva manoeuvre and cough impulses to exclude hernias. Varicoceles apparent only as a cough impulse or just detectable on Valsalva were categorized as sub-clinical. Palpable venous masses were categorized 1 to 4 according to extent (Grade 2 extends to testis, Grade 3 extends behind testis and Grade 4 (bag of worms, virtually envelops, even conceals, the testis).

Abdominal examinations, with patient recumbent was conducted according to clinician discretion; generally when there had been previous abdominal history; a Grade 4 varicocele was detected; or symptoms such as abdominal pain or swelling dictated a need (approximately 20%). Rectal examinations were conducted only according to symptoms of prostatism or if dictated on ultrasound evidence of prostatic disorder.

Statistics

All data has been tabulated and observations defined with respect to specificity ie sensitivity (TP; true positives) and no pathology (TN; true negative). The fall-out rate (FP; false positive) and missed diagnoses (FN; false negative) are also shown. Where relevant this was checked against semen analyses for predictive value. The testicular cancer data was also checked against the ultrasound findings for predictive value. The definition of predictive value is that derived from Bayes’ theorem and defines:

Positive predictive value PPV as the number of true positives over the total number of positive calls. Negative predictive value is the number of true negatives over the total number of negative calls.

Results

Patients

A total of 1203 men completed this study. Their ages ranged between 21 and 68 years and all were partners within an infertility setting (Figure 1). The clinicians undertaking the clinical examinations of the men were all consultant specialists in obstetrics and

gynaecology. Of the 6 clinicians, two had an additional specialty qualification in general surgery, but cases were evenly distributed among all the clinicians. One of the gynaecologists with additional surgical qualification (AMJ) practiced as a Consultant Andrologist and often provided second-opinion advice to the others who sometimes were uncertain regarding the detection of vas deferens, distended epididimides (Bayle’s sign) and the presence of Grades 1 and 2 varicoceles.

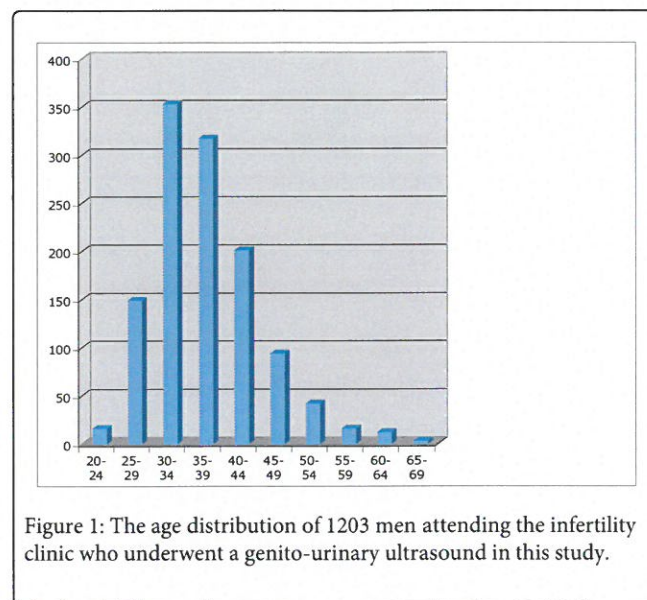


Figure 1: The age distribution of 1203 men attending the infertility clinic who underwent a genito-urinary ultrasound in this study.

In this group of patients only the most obvious lesions had been detected clinically and these included 2 men with Prune Belly Syndrome [9] which of course had been diagnosed at birth. Also detected clinically were the larger hydroceles. However many of these patients’ notes were poorly annotated and it was often not possible to quantify the effects or the value of the clinical history or the value of examination on the arrival at any diagnosis in these men e.g. all the testicular cancers as well as the renal tumour were undetected (no masses described).

The prevalence of ‘fertile or ‘infertile’ semen analyses in the 1203 patients in this study

Of the 1203 men in the study the semen displayed normal parameters “fertile” in 748 (62%) and subnormal parameters “subfertile” in the remaining 455 men.

Overall, the aspect of semen analysis bore no direct relationship to ultrasound findings, whether or not varicoceles were included in the studies, except where noted under specific findings as follows:

The lesions detected by the genito-urinary ultrasound examination

A wide range of pathologies was demonstrated in this study and each lesion or group of lesions is described below.

Testicular cancer (n=5)

A total of 5 men making up 0.4% of the total were found to have a germ cell tumour of one testis. The size of these tumours varied from 1.1-3.4 centimeters and have been described more fully elsewhere [10].

The semen was infertile in 3 of these 5 men but was deemed to be fertile in the remaining 2 men. None of these tumours were detected clinically although the Consultant Urologist who later examined the more extensive tumour suspected a “textural difference” in the affected testis.

Leydig cell tumour (n=1)

One further man had a testis containing a tumour that initially was thought to be cancer but proved to be a benign Leydig cell tumour. There was no apparent gynecomastia in this man but the semen was defined as being subfertile. Neither the gynecologists nor the referred Urologist could detect the lesion clinically.

Ischaemic area of the testis (n=3)

Three men had large areas of what was believed to be ischaemic change in one testis. In one of these 3 men, this was mistaken for a tumour on the appearances of a tertiary ultrasound and the man underwent an “unnecessary” orchidectomy. The cause of this ischaemia remained undefined. All three of these men had a subfertile semen analysis but none of the lesions could be detected clinically.

From the aforementioned cases a predictive value (PV) could be calculated for the 9 cases of hypochoic region in the testis; those cases were all referred to Urologists.

Seven men had an orchidectomy performed for suspected cancer but only 5 of those cases revealed cancer (seminoma) - one proved to be a Leydig cell tumour (benign) and the other was an ischaemic degeneration giving a false diagnosis on ultrasound (by 2 separate Consultants).

- The TP rate (sensitivity) for testicular tumour was 100%
- The FP rate (fall-out) was 29%
- The TN rate (correctly diagnosed as non-cancer, i.e. healthy) appears to be 100%
- The FN rate (incorrectly diagnosed as non-cancer) appears to be zero
- The PV was 71%

Testicular cysts and calcification (n=11)

A small solitary cyst was present in one testis in a group of 8 men. In a further 3 patients there was calcification both in and around the testes. One of these men had recently undergone a testicular biopsy that could have resulted in the cyst perhaps by representing the site of an infarct. The surrounding calcification may also be the result of some form of peri-testicular haemorrhage. None of these lesions were clinically detected.

Testicular Microlithiasis (n=66)

A total of 66 (6%) of these men were found to have the change known as testicular microlithiasis. Of these men, the change was present bilaterally in 49 men and unilaterally in 17 of them (Table 1). This lesion is known to be associated with intra-tubular seminoma of the testis and was indeed present in one of the 5 men with a seminoma. None were clinically detected. A specific presentation on the subject of testicular Microlithiasis which comprises an extended data-set has recently been reported by us. It does imply a greater incidence with subfertility [11].

Prune Belly syndrome	2
Renal Cysts	21
Unilateral Duplex kidney	9
Unilateral Renal Agenesis	5
Unilateral Renal Atrophy	4
Hydronephrosis	2
Horseshoe Kidney	21
Pelvi-ureteric Junction Obstruction (PUJ)	9
Transplanted Pelvic Kidney	5
Renal Stone	4
Left Renal Tumour (probable Grawitz)	3
Total	52

Table 1: The lesions of the renal tract that were identified among the patients in this study.

Cystic ectasia of the testis (n=15)

This lesion consists of a dilatation of the rete testis [12] and is thought to be a cause of infertility. It was present in 15 (1.2%) of the men in this study (Figure 2). This lesion was bilateral in 5 men and unilateral in the remaining 10 men. The semen was infertile in 10 of these 15 men but one of these 10 men had undergone a vasectomy in the past. The lesions were not clinically detectable.

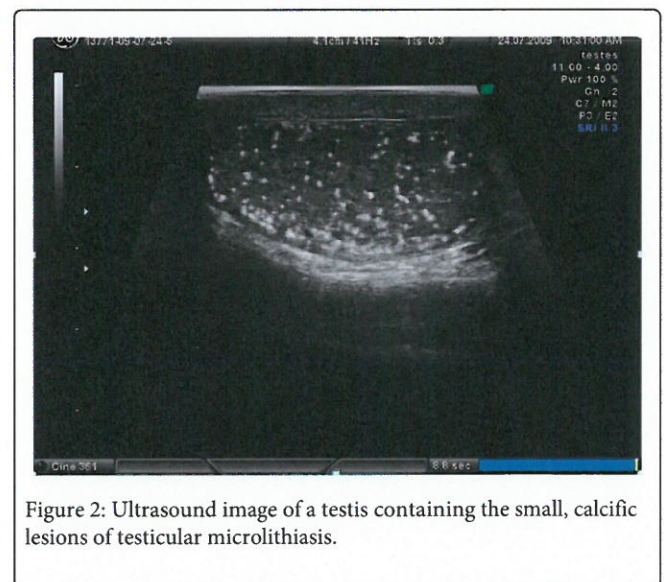


Figure 2: Ultrasound image of a testis containing the small, calcific lesions of testicular microlithiasis.

Although cystic ectasia is thought to represent obstruction in the vasa efferential tubules or nearby vas with retrograde pressure effect, one of the men who was found to have a bilateral lesion also had a normal semen analysis [13]. In this case at least the lesion may not at times be a cause of infertility.

Lesion	No
--------	----

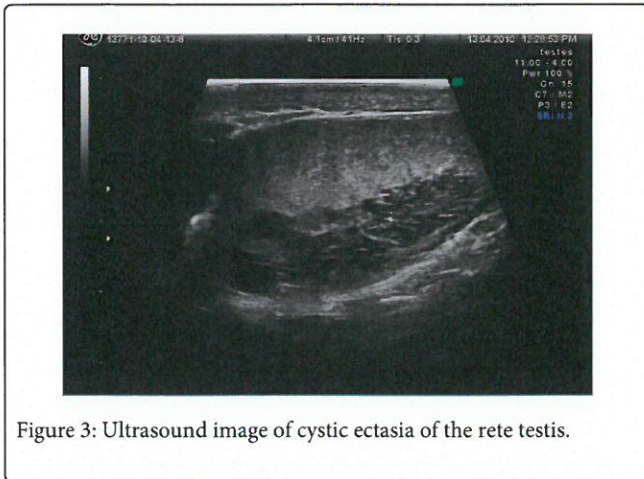


Figure 3: Ultrasound image of cystic ectasia of the rete testis.

Renal lesions (n= 52)

This was one of the largest groups of patients in this study. And made up around 5% of all the patients in this study. However only a few of these lesions could be considered even remotely life-threatening and thus really only one of these renal lesions (renal tumour) posed any immediate threat to either the patient’s health or welfare or even to his infertility.

Renal cysts were a common finding and were present in 21 of these 52 men. In one man, multiple cysts were present in both kidneys but a plentiful amount of parenchyma was present between these cysts thus excluding the dangerous condition known as renal polycystic disease.

Some 9 men had a duplex kidney and a further 5 men were found to have unilateral renal agenesis. One man was, for the first time, found to have a horse-shoe kidney. A further 3 men were found to have a unilateral hydronephrosis while a mild degree of pelvi-ureteric junction obstruction was present in another 4 men. One man had a pelvic kidney following a kidney transplant. A small calyceal stone was present in one further patient.

Probably only one patient had a lesion that threatened life and that was one man who was found to have a 4cm renal tumour, he was referred to a public urology clinic but was lost to our follow-up; we believe he had a Grawitz tumour. The tumour was not clearly palpable clinically; perhaps vaguely once the ultrasound evidence was shown.

Only 1 of the 52 men listed in Table 2. had a clinically palpable kidney (pelvic).

Lesion	No	PPV
Testicular cancer	5	60%
Leydig cell tumour	1	100%
Testicular microlithiasis	66	46%
Testicular cysts & calcification	11	27%
Testicular Ischemia	3	100%
Cystic ectasia of the rete testis	15	60%
Renal lesions	52	28%
Prostatic lesions	4	50%

Hydrocele	31	45%
Spermatocele	9	100%
Lesions outside the renal tract	13	23%
Total	210	43%

Table 2: The lesions found on ultrasound - among a group of 1203 men attending an infertility clinic, excluding varicoceles which were detected in 625 cases (52%) and 262 cases with epididymal cysts (22%). *7 spermatoceles in cases of vasectomy. PPV denotes percent with semen analysis classified abnormal.

Prostatic disorders (n=4)

A small group of 4 patients were found to have a prostatic lesion. In 3 of these men, this was simply a mild to moderate enlargement (only one classified enlarged clinically) but in the remaining patient, a utricular cyst was present.

This cyst was 1.5 centimeters in diameter and may give rise to azoospermia sometime in the future. However at the time of his semen analysis, the ejaculate was deemed to be normally fertile. The prostate gland in this man was considered clinically normal.

Hydrocele (n=31)

This was also a common lesion in this study. Of these 31 hydroceles, some 10 were bilateral and the remainders were unilateral. The cause of these hydroceles was not clear. The gynecologist reported suspicion of hydroceles in only 5 cases.

Spermatocele (n=9)

These were present in 9 men of which 7 of these lesions were associated with the presence of an unreversed vasectomy. The Spermatocele was present bilaterally in 7 of these men and unilaterally in the remaining 2 men. The formation of a Spermatocele is a common complication of vasectomy and its presence may account for the failure of a reversal. The gynecologists detected 3 cases, mostly when the lesions were 2 cms in size.

Epididymal or para-epididymal cyst (n=262)

This is clearly a very common change that is seen on ultrasound and can probably view as a variant of normal. As 107 of these 262 men had a fertile semen analysis, they are unlikely to be an important cause of infertility, if at all. The gynecologists detected cysts around 2 cms or greater, the smaller ones being ignored or not detected.

Varicocele (n=625)

Among these patients undergoing a genito-urinary ultrasound examination, a total of 625 (52%) were reported to have a varicocele. However of those 625 men with a varicocele, only 283 men had a semen analysis that was considered to be abnormally 45% of varicoceles.

The vast majority of the varicoceles categorized Grade 2 or higher were left sided (428 left only, 80 bilateral and only 7 right sided only). The majority of these varicoceles were categorized by ultrasound as Grade 2 but 185 cases (32%) were large being graded 3 & 4. Volumetric differences between left and right testis in this group showed 275 men with reductions of ≥3ml (55%) and 73 with

reductions ≥ 5 ml (15%). There were 15 cases with a differential reduction of 7 ml (3.5%).

The argument about the place of varicocele in the causation of male infertility continues and is under separate study by our group but there does appear a direct correlation with severity of semen parameter disturbance and degree of volumetric difference between the testes.

Vasectomy (n=101)

A total of 101 men came to the fertility clinic with a now unwanted vasectomy in position. Interestingly no comment was made concerning the presence of the vasectomy by the sonographers nor was there any mention of the gross distortion of the epididymis or in the vas in these patients especially among men with very long vasectomy intervals where these changes are known to be especially marked. Very few men had any detectable nodules at the site of their previous vasectomy.

Lesions unrelated to the genito-urinary tract (n=13)

In this group of patients, 4 men were found to have hepatosplenomegaly and one more had splenomegaly. Gallstones were present in 3 men while microcalculi were present in the gall bladder of one further man. In one of these male patients, a liver cyst was present while a liver haemangioma was present in one other man. In two more of these patients, both of whom were obese, a fatty liver was seen.

Discussion

In this study a large number of both gonadal as well as extra-gonadal lesions were identified by the routine use of ultrasound in this large group of infertile men. Very few lesions were detected by the gynecologists examining these men in an infertility setting.

Testicular cancer was present in 5 men in this study confirming the increased incidence of testicular germ cell tumours in the infertile male [14,15]. Even though the prognosis following treatment is good in men with this type of testicular tumour, early diagnosis may allow for testis sparing, namely the removal of the tumour without removal of the whole testis [16]. Provided the tumour is small, such a procedure is certainly possible.

In our series the PPV for testicular cancer was 71% and this meant 2 men had orchidectomy performed "unnecessarily" in retrospect. One might argue that Urologists reviewing such asymptomatic men in sub fertile settings should undertake an observation period prior to consideration of orchidectomy, or consider more conservative surgery; however that is an issue for the Oncological Urology Societies to consider. Until now such men did not see urologists; infertility doctors simply working with the semen sample. We would argue for a better approach.

The large number of men with testicular microlithiasis was a surprise. This lesion is known to be associated with germ cell intratubular neoplasia of the testis and thus men with this condition require follow up as around 50% will develop germ cell cancers within the next 6 years [17].

A total of 15 men were found to have cystic ectasia of the rete testis [10,12,18,19]. It is not known for sure whether this is in itself a cause of infertility but as for the most part it can only be diagnosed on ultrasound examination, it is important that we develop further knowledge about this condition as well as its possible role in infertility.

The common occurrence of renal lesions was also an important finding as some of these lesions, in particular those with atretic kidneys or any form of obstructive lesion of the calyceal or ureteric systems.

The prostate is an organ that receives little attention in an infertility clinic. Today there are large numbers of men who attend infertility clinics who are also over 40 years of age and a rising number who are over 50 years of age. Prostate cancer is thus always a possible complication of their infertility among men in these age groups and thus its presence should always be sought among such patients.

In keeping with our long-standing views, the data showed poor predictive value from semen analysis and, although not studied in this report, translates also to subsequent fertility [20], it is very likely that some of these 'subfertile' semen analyses would, in time, be of a sufficient quality to generate a natural pregnancy; likewise many of the so called 'fertile' semen analyses could prove to be inadequate for this purpose. Thus the separation of fertile and subfertile semen analyses in this study cannot be deemed an entirely accurate or relevant categorization. In fact, we would argue that undertaking a semen analysis simply denotes the presence or absence of sperm, and this may be sufficient for assisted reproduction.

From this study, it is thus recommended that genito-urinary ultrasound examination is a useful part of the evaluation of the infertile male. Such a procedure will diagnose lesions that cannot be diagnosed on clinical examination and can provide information about abnormalities whose role in the generation of infertility cannot otherwise be ascertained.

We would recommend that a genitourinary ultrasound is of more value than a simple testicular ultrasound examination as in the former information about the kidneys can be obtained particularly in view of the large number of men with renal abnormalities seen in this study.

References

1. Jequier AM (2004) Clinical andrology: still a major problem in the treatment of infertility. *Hum Rep* 19: 1245-1249
2. Tomlinson MJ, Kessopoulou E & Barratt CLR (1999) The diagnostic and prognosis of traditional semen analysis. *J Androl* 20, 588-593.
3. Lefevre L, Bedu-Addu K, Connor SJ, et al. (2007) Counting sperm does not add up any more: time for a new equation. *Reproduction* 133: 556-684.
4. McDonough PG (1997) Has traditional semen analysis lost its clinical relevance? *FertilSteril* 67: 586-587.
5. Gill B, Kogan S, Starr S et al. (1989) Significance of epididymal and ductal abnormalities associated with testicular descent. *J Urol* 142: 556-558.
6. Little AF, Lavoipierre AM (2002) Unusual clinical manifestations of the Nutcracker Syndrome. *Australas Radiol* 46: 197-200
7. World Health Organisation (1999) 'Laboratory Manual for the Examination of Spermatozoa and Sperm-Cervical Mucus Interaction', 4th Edition, Pubs Cambridge University Press, Cambridge.
8. Jequier AM (2008) *Male Infertility: a guide for the Clinician*. Wiley Press pp 384.
9. Woods AG, Brandon DH (2007) Prune Belly Syndrome. A focussed physical assessment. *Adv Neonatal Care* 7: 132-143.

10. Phillips N, Jequier AM (2007) Early testicular cancer: a problem in an infertility clinic. *Reprod Biomed Online* 15: 520-525.
11. Jequier AM, Phillips N, Yovich JL (2014). Testicular Microlithiasis among Infertile Men: A reason for concern? *Androl Gynecol Curr Res* 2: 2.
12. Burrus JK, Lockhart ME, Kenney PJ, et al. (2002) Cystic ectasia of the rete testis: clinical and radiographic features. *J Urol* 16: 1436-1438.
13. Jequier AM, Phillips N (2009) Cystic dilatation of the rete testis: a hidden diagnosis among infertile men. *Reprod Biomed Online* 18: 190-194.
14. Mancini M, Campignani L, Gazzano G, et al. (2007) High prevalence of testicular cancer in azoospermic men without spermatogenesis. *Br Med J* 22, 559-562
15. Raman JD, Norbert CF, Goldstein M (2005) Increased incidence of testicular cancer in men presenting with infertility and abnormal semen analysis. *J Urol* 174: 1819-1822.
16. Colpi GM, Carmigni L, Nerva F, et al. (2005) Testicular sparing microsurgery for suspected testicular masses *BJUI* 96: 64-69.
17. Bettocchi C, Coker CB, Deakin J, et al. (1994) A review of testicular intratubular germ cell neoplasia in infertile men. *J Androl* 15 Supplement: 14S-16S
18. Nistal M, Jimenez-Hefferman JA (1995) Rete testis dysgenesis. A characteristic lesion of undescended testes. *Arch Lab Path Med* 121: 1259-1264.
19. Colangelo SM, Fried K, Hyacinthe LM, et al. (1975) Tubular ectasia of the rete testis; an ultrasound diagnosis. *Urology* 45: 532-534.
20. Polansky FF, Lamb EJ (1988) Do the results of semen analysis predict future fertility – A Survival Analysis Study. *Fertil Steril* 49: 1059-1065.