

Case Report

Preconception Laparoscopic Cervical Cerclage: The Preferred Technique for Cervical Incompetence?

Kedar R Jape¹, Philip K Rowlands¹ and John L Yovich^{1-3*}

¹PIVET Medical Centre, Leederville, Perth WA 6007, Australia

²Cairns Fertility Centre, Cairns QLD 4870, Australia

³School of Biomedical Sciences, Faculty of Health Sciences, Curtin University, Bentley, Perth WA 6102, Australia

Abstract

Objective: To explore the ease and effectiveness of placing a cervical suture preconception using a laparoscopic technique.

Design: A case study with systematic literature review.

Setting: PIVET Medical Centre, a private facility providing comprehensive services over 35 years in gynaecology, andrology and reproductive endocrinology for infertility and recurrent pregnancy loss.

Patients: Case report of a 35 year old woman with recurrent mid-trimester pregnancy losses and well-define cervical incompetence.

Intervention: Preconception placement of cervical suture by laparoscopic trans-abdominal cerclage (LTAC) as a day case.

Main outcome measure: Details of ensuing pregnancy.

Results: Conception without delay and normal pregnancy with delivery by elective caesarean section near term of healthy 2645 g female infant.

Conclusion: We are impressed with the ease of the LTAC technique which appears likely to have fewer complications than traditional vaginal techniques, as well as speedier recovery compared to a laparotomy approach.

Keywords: Laparoscopic cervical cerclage; Cervical incompetence; Vaginal technique; Laparotomy technique; Transabdominal cervical cerclage

Introduction

Cervical incompetence is defined as inability of the uterine cervix to retain a pregnancy in the second trimester, in the absence of contractions as outlined by The American College of Obstetrics and Gynecology [1]. The lack of a confirmatory diagnostic test as well as absence of a universally accepted definition of cervical incompetence puts diagnosis of this condition totally in a clinical perspective. A classical history of painless dilatation and cervical shortening after the first trimester in the absence of preterm labour with subsequent expulsion of products of conception and no underlying evidence of co-existing pathology (such as infection, ruptured membranes, congenital chromosomal anomalies or intra-uterine bleeding) is indicative of cervical incompetence. Cervical incompetence is estimated to complicate between 0.1% to 2% of all pregnancies and accounts for 15% of habitual preterm deliveries between 16 and 28 weeks of gestation [2].

Shirodkar [3] described the first cervical cerclage suture in 1955. This technique involved vaginal placement of suture high over the cervix, reflecting the bladder and burial of the knot. Elective Caesarean section was recommended as the stitch was not easily removed. Western Australia born McDonald [4] modified and simplified this technique, reporting from Melbourne in 1957. His technique involved a purse string stitch inserted at a lower level than the Shirodkar suture, without dissection and leaving the knot exposed. This knot could be removed at 37 weeks to facilitate vaginal delivery. Since its first description in 1965 [5], trans-abdominal cervical cerclage prior to pregnancy has emerged as a safe and effective intervention for improving outcomes [6-9]. Recently, the laparoscopic approach has taken this procedure a step further by reducing hospital stay as well as showing the potential to improve pregnancy related outcomes. Hence, we report an interesting

case of laparoscopic pre-conception cervical cerclage resulting in a positive outcome both for the mother and baby.

Case Description

A 35 year old woman, gravida 4 para 1 presented to our practice with previous history of spontaneous onset preterm labour at 26 weeks in her first pregnancy. She underwent Caesarean section as the baby presented as footling breech with rupture of membranes. Her antenatal ultrasound scans were suggestive of a bicornuate uterus. Subsequently, as a part of investigation for underlying chronic pelvic pain, she underwent hystero-laparoscopy and excision of endometriosis. During this procedure, she was noted to have a septate uterus. As a follow up procedure at PIVET, she had a hysteroscopic complete septal resection for a 6 cm long broad based septum under laparoscopic guidance. At that procedure her cervix was noted to be patulous and partially open with easy passage of an 8 mm Hegar dilator. Within two years of this procedure, she conceived spontaneously and had elective McDonald's cervical stitch placed at 12 weeks following a normal first trimester

***Corresponding author:** John L Yovich, Medical Director and Consultant in Gynaecology, Andrology and Reproductive Medicine, PIVET Medical Centre 6007 and Cairns Fertility Centre 4870 and Clinical Professor, School of Biomedical Sciences, Faculty of Health Sciences, Curtin University, Perth Western Australia 6845, Tel: (08) 9422 5400; Fax: (08) 9382 4576; E-mail: jyovich@pivet.com.au

Received November 30, 2015; **Accepted** December 13, 2015; **Published** December 20, 2015

Citation: Jape KR, Rowlands PK, Yovich JL (2015) Preconception Laparoscopic Cervical Cerclage: The Preferred Technique for Cervical Incompetence? JFIV Reprod Med Genet 4: 164. doi:10.4172/2375-4508.1000164

Copyright: © 2015 Jape KR, et al. This is an open-access article distributed under the terms of the Creative Commons Attribution License, which permits unrestricted use, distribution, and reproduction in any medium, provided the original author and source are credited.

screen (FTS). However four weeks later she developed spontaneous rupture of membranes, following which the cervical suture was removed with consequent spontaneous miscarriage. Thereafter, she presented with two episodes of delayed miscarriages in a span of 12 months, despite the concomitant use of medroxyprogesterone acetate tablets 20 mg thrice a day as per PIVET's long-standing protocol for recurrent pregnancy loss [10,11]. Hence, the decision to perform preconception laparoscopic cervical cerclage was taken.

At examination under anaesthesia, the cervical os was noted to be patulous, easily admitting an 8 mm Hegar dilator. The pelvic features were otherwise normal. A Spackman cannula was placed for uterine manipulation and 4-port laparoscopy was performed. Noting normal pelvic features the utero-vesical fold was opened anteriorly and the bladder was reflected caudally. From the posterior aspect, the uterine artery was identified and a window was created in the broad ligament in an avascular plane at a position medial and distal to the uterine artery ensuring the ureters were clearly sighted laterally. These 5-6 mm broad ligament windows were created on both sides at a level just inferior to the uterine isthmus. A 5 mm Mersilene tape (non-absorbable polyester braided suture; Ethicon, Johnson & Johnson, USA) with needles removed was passed through these windows from the anterior aspect bilaterally (Figure 1) ensuring that the free ends lay posteriorly. Intracorporeal suturing was performed creating a knot at the posterior aspect of the uterus at the level of the utero-sacral crus (Figure 2). Post-

procedure, bilateral ureteric vermiculation and well perfused uterus were confirmed visually. Postoperatively, the patient recovered well and was discharged home the same evening, 6-hours post-procedure.

This patient had one normal period after surgery and conceived spontaneously. At anatomy scan, cervical length was 3.3 cm which remained unchanged at third trimester scans. At 36+3 weeks, she presented in early labour and had elective caesarean section with delivery of a lusty female infant weighing 2654 g. At the caesarean section the Mersilene tape was clearly seen at the level of the isthmus posteriorly with intact knot, without any reactionary adhesions. Anteriorly, it was totally invisible being covered inside the utero-vesical fold. The tape was removed from the posterior aspect as the woman requested this and was not desiring a future pregnancy. Her postoperative recovery was entirely uneventful.

Ethical Issues

PIVET Medical Centre and Cairns Fertility Centre are both accredited by the Reproductive Technology Accreditation Committee with annual scrutiny of all cases proceeding into assisted reproductive procedures. Clinical processes are considered by Bellberry Human Research Ethics Committee since 2004 with the most recent site visit in October 2014, for review 2016; whilst academic research projects are considered by Curtin University Ethics Committee. This case report is approved by Bellberry under general ethical considerations for clinical and operative procedures including patient information documentation for informed consent, P1009a as well as Curtin approving the publication of this retrospective data with approval number RD_25-15.

Discussion

Laparoscopic transabdominal cerclage (LTAC) is a procedure where a suture is placed around the cervix at its uppermost part at the cervico-uterine transition where the uterine isthmus forms. It compares favourably with the laparotomy approach to cerclage [12-15] but with the full benefits of a brief laparoscopic operation. The cervico-isthmus level, being the site of placement for the LTAC cannot be easily reached through a vaginal approach without major dissection or clear perception of anatomy, hence the laparoscopic approach offers greater advantage with reduced hospital stay. Risk factors are similar to any other minor pelvic laparoscopic procedure and we would believe the risk of suture-site infection is reduced as there is no exposure to vaginal flora.

LTAC is indicated if the cervix is fore-shortened eg. post-cone biopsy; or irregular from obstetric trauma; or if there has been a previous preterm pregnancy/ foetal loss in the absence of uterine contractions; or a history of a failed transvaginal cerclage [16]. Our patient fulfilled all the above criteria for prerequisites to this procedure. Ideally, it is to be performed pre-pregnancy due to the physiologic advantages of a small, minimally vascular uterus where manipulations can be performed readily and safest. However, we would believe LTAC can also be performed up to 14 weeks gestation after normal FTS, when pregnancy is classified as ongoing. The benefits include reduced potential of migration of the inert suture due to its proximal placement. This technique also avoids the presence of foreign body in vagina, which could be a potential source of cervico-vaginal infection, causing chorioamnionitis and precipitating premature rupture of membranes and preterm labour. In addition, the suture can be left intact for future pregnancies. It does not affect future fertility status. In situations like early miscarriages, it does not affect the ability to perform dilatation and curettage (D&C) as the suture is not extremely tight. The only disadvantage of this procedure is that caesarean section is recommended

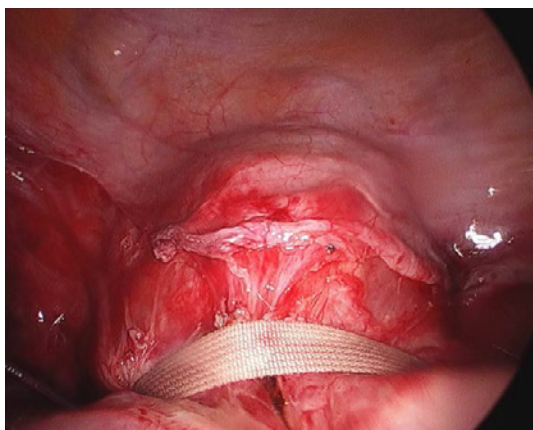


Figure 1: Mersilene tape placed at cervico-isthmus junction after opening the utero-vesical fold and reflecting the bladder caudally.

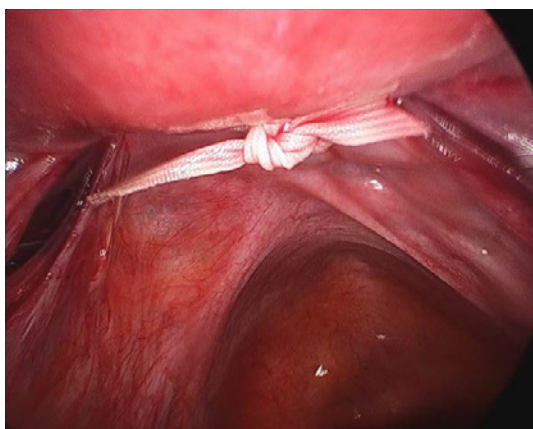


Figure 2: Mersilene tape tied posteriorly at the level of the utero-sacral crus on the supravaginal part of the cervix.

as removing this suture vaginally is practically impossible and should not be attempted. We suspect it could be removed laparoscopically and in the event of mid-trimester foetal demise, hysterotomy would be recommended.

The current evidence conflicts with the British RCOG (Royal College of Obstetricians and Gynaecologists) recommendations [17] stating that "There is no evidence to support laparoscopy over laparotomy for the insertion of abdominal cerclage." However, a recent systematic review by Tulandi et al. [18] from Canada evaluated 16 studies of abdominal cerclage (N=678 cases) and concluded that the rates of third trimester delivery and live birth after abdominal cerclage via laparoscopic approach were higher and comparable to those via laparotomy. They also concluded that pre-conception cerclage was more pragmatic and preferable than post-conception.

Conclusion

In conclusion, we present this case of LTAC as few cases have so far been reported. However given our long experience in managing infertility and recurrent fetal wastage, we have been impressed with the simplicity and ease of application of this procedure. There appear to be obvious benefits over existing trans-vaginal and trans-abdominal management strategies. We will increasingly explore LTAC and encourage other gynaecologists managing similar cases.

References

1. American College of Obstetricians and Gynecologists (2014) ACOG Practice Bulletin No.142: Cerclage for the management of cervical insufficiency. *Obstet Gynecol* 123: 372-379.
2. Rand L, Norwitz ER (2003) Current controversies in cervical cerclage. *Semin Perinatol* 27: 73-85.
3. Shirodkar VN (1955) A new method of operative treatment for habitual abortion in the second trimester of pregnancy. *Antiseptic* 52: 299-303.
4. McDonald IA (1957) Suture of the cervix for inevitable miscarriage. *J Obstet Gynaecol Br Emp* 64: 346-350.
5. Benson RC, Durfee RB (1965) Transabdominal cervicouterine cerclage during pregnancy for the treatment of cervical incompetence. *Obstet Gynecol* 25:145-155.
6. Gibb DM, Salaria DA (1995) Transabdominal cervicoisthmic cerclage in the management of recurrent second trimester miscarriage and preterm delivery. *Br J Obstet Gynaecol* 102: 802-806.
7. Anthony GS, Walker RG, Cameron AD, Price JL, Walker JJ, et al. (1997) Transabdominal cervico-isthmic cerclage in the management of cervical incompetence. *Eur J Obstet Gynecol Reprod Biol* 72: 127-130.
8. Lotgering FK, Gaugler-Senden IP, Lotgering SF, Wallenburg HC (2006) Outcome after transabdominal cervicoisthmic cerclage. *Obstet Gynecol* 107: 779-784.
9. Groom KM, Jones BA, Edmonds DK, Bennett PR (2004) Preconception transabdominal cervicoisthmic cerclage. *Am J Obstet Gynecol* 191: 230-234.
10. Yovich JL, Willcox DL, Wilkinson SP, Poletti VM, Hähnel R (1985) Medroxyprogesterone acetate does not perturb the profile of steroid metabolites in urine during pregnancy. *J Endocrinol* 104: 453-459.
11. Yovich JL, Turner SR, Draper R (1988) Medroxyprogesterone acetate therapy in early pregnancy has no apparent fetal effects. *Teratology* 38: 135-144.
12. Carter JF, Soper DE, Goetzl LM, Van Dorsten JP (2009) Abdominal cerclage for the treatment of recurrent cervical insufficiency: laparoscopy or laparotomy? *Am J Obstet Gynecol* 201: 111.
13. Whittle WL, Singh SS, Allen L, Glaude L, Thomas J, et al. (2009) Laparoscopic cervico-isthmic cerclage: surgical technique and obstetric outcomes. *Am J Obstet Gynecol* 201: 364.e1-7.
14. Sheehan P, Ades A, Palma-Dias R (2008) Experience with laparoscopic transabdominal cervico-isthmic cerclage. *Aust N Z J Obstet Gynaecol* 48: 448.
15. Lesser KB, Childers JM, Surwit EA (1998) Transabdominal cerclage: a laparoscopic approach. *Obstet Gynecol* 9: 855-856
16. Ades A, Dobromilsky KC, Cheung KT, Umstad MP (2015) Transabdominal Cervical Cerclage: Laparoscopy versus Laparotomy. *J Minim Invasive Gynecol* 22: 968-973.
17. Royal College of Obstetricians and Gynaecologists (RCOG) guidelines (2011) Cervical cerclage, Green top guideline number 60.
18. Tulandi T, Alghanaim N, Hakeem G, Tan X (2014) Pre and post-conceptual abdominal cerclage by laparoscopy or laparotomy. *J Minim Invasive Gynecol* 21: 987-993.

Citation: Jape KR, Rowlands PK, Yovich JL (2015) Preconception Laparoscopic Cervical Cerclage: The Preferred Technique for Cervical Incompetence? JFIV Reprod Med Genet 4: 164. doi:[10.4172/2375-4508.1000164](https://doi.org/10.4172/2375-4508.1000164)

OMICS International: Publication Benefits & Features

Unique features:

- Increased global visibility of articles through worldwide distribution and indexing
- Showcasing recent research output in a timely and updated manner
- Special issues on the current trends of scientific research

Special features:

- 700 Open Access Journals
- 50,000 editorial team
- Rapid review process
- Quality and quick editorial, review and publication processing
- Indexing at PubMed (partial), Scopus, EBSCO, Index Copernicus and Google Scholar etc
- Sharing Option: Social Networking Enabled
- Authors, Reviewers and Editors rewarded with online Scientific Credits
- Better discount for your subsequent articles

Submit your manuscript at: <http://www.omicsgroup.org/journals/submission>