



# Sperm Recovery for Men with Spinal Cord Injury: Vasal Flush is the Preferred Method for An-ejaculatory Males

John L Yovich<sup>1\*</sup>, Darren Katz<sup>2</sup> and Anne M Jequier<sup>3</sup>

<sup>1</sup>Curtin University, Perth Western 6845, Australia

<sup>2</sup>Men's Health Melbourne, 233 Collins Street, Melbourne, Victoria 3000, Australia

<sup>3</sup>Retired to 8 Blind Lane, Keyworth Nottingham, WG12 5GH, UK

## Abstract

**Objective:** To determine the preferred technique for surgical sperm retrieval from an-ejaculatory males with spinal injury requiring assisted reproduction.

**Design:** A case study with literature review.

**Setting:** PIVET Medical Centre, a private facility providing comprehensive services over 38 years in gynaecology, andrology and reproductive endocrinology for infertility and recurrent pregnancy loss.

**Patients:** Case report of a couple where the 34-year old male is paraplegic from a complete T12 spinal lesion occurring at age 27 years from a skiing accident. He remained an-ejaculatory despite conservative treatments. This case is examined in the setting of extensive experience by the 3 authors ranging 20-40 years in managing spinal-injured males.

**Intervention:** Applying microsurgical techniques, open scrotal sperm recovery from the Vas, the epididymis and the testis undertaken.

**Main outcome measure:** Details of sperm recovery, sperm cryopreservation, subsequent IVF and resultant pregnancies. Best sperm samples from Vasal Flush.

**Results:** Conception 4 months after following a single blastocyst transfer where fertilization was achieved using sperm retrieved from the Vasal Flush technique. The resultant pregnancy was entirely normal and a healthy male was delivered from spontaneous vaginal delivery with birth weight 3600 g.

**Conclusion:** The Vasal Flush technique provided the best sperm samples and is recommended for an-ejaculatory males regardless of the underlying disorder. The technique can be performed as an isolated minimally invasive surgical method of sperm retrieval, potentially under local anaesthesia.

**Keywords:** Spinal injury; Aspermia; Anejaculatory males; Vasal flush; MESA; TESE; IVF

## Introduction

The forty years since the birth of the first IVF infant has seen the entire spectrum of fertility, infertility and management of issues related to human reproduction, change in so many aspects. Even the main drive for the development of assisted reproduction, namely tubal factor infertility has diminished so that male factor causes as well as unexplained or poorly explained causation now dominate at the present time. This has led to appeals for an increased focus on the male across all the fertility issues [1]. One such area concerns reproductive problems in the male with spinal cord injury (SCI).

## Overview of the SCI Male

The reproductive potential of men with SCI is compromised for three major reasons [2]. Firstly, erectile function is affected to a degree which is dependent upon the level of the spinal cord injury, as well as completeness of the neurological damage; complete transection having the worst outcome. The erectile process in all men is dependent upon reflex sensitivity (touching the genitalia or other erogenous zones), psychogenic responses (general arousal stimuli vs inhibitory stimuli from discomfort, pain or distress) and spontaneous (usually nocturnal) erections. Secondly, the ejaculatory process may be compromised if semen fails to enter the posterior urethra to trigger reflex expulsion of the semen through the penile urethra and the urethral orifice. Thirdly, testicular function is often compromised with reduced function of the Leydig cells causing reduced testosterone output and disorder of

the Sertoli cells as well as the accessory glands which become affected by recurrent inflammation secondary to urinary tract infections. The ejaculatory ducts may become blocked but even where semen can be retrieved, there is often a high level of DNA fragmentation in the ejaculates due to elevated levels of reactive oxygen species (ROS) resulting from chronic or repetitive inflammation as well as degenerative sperm from stagnation arising from failure of the natural clearing process of ejaculation [3]. All this means that the majority of semen samples arising from SCI males tend to be of suboptimal quality, unless the male is ejaculating reasonably frequently, although studies are inconclusive on this point.

## Achieving ejaculation

Some men with SCI actually can achieve ejaculation, especially when assisted by a sensitive partner and where the process is initiated

**\*Corresponding author:** John L Yovich, Curtin University, Perth Western 6845, Australia, Tel: +61 419 906 953/+61 8 9422 5400; Fax: +61 8 9382 4576; E-mail: [jlyovich@pivet.com.au](mailto:jlyovich@pivet.com.au)

**Received** November 26, 2018; **Accepted** December 11, 2018; **Published** December 18, 2018

**Citation:** Yovich JL, Katz D, Jequier AM (2018) Sperm Recovery for Men with Spinal Cord Injury: Vasal Flush is the Preferred Method for An-ejaculatory Males. J Fertil In vitro IVF Worldw Reprod Med Genet Stem Cell Biol 6: 209. doi: [10.4172/2375-4508.1000209](https://doi.org/10.4172/2375-4508.1000209)

**Copyright:** © 2018 Yovich JL, et al. This is an open-access article distributed under the terms of the Creative Commons Attribution License, which permits unrestricted use, distribution, and reproduction in any medium, provided the original author and source are credited.

early after the injury. Good general health and a positive psychological attitude are also beneficial. However, many SCI men remain an-ejaculatory and require assistance for reproduction. For many cases this can be achieved by penile vibratory stimulation (PVS) although such devices require being of sufficient amplitude for effectiveness. A couple of suitable commercial devices are available (Ferticare and Vibrect [2]), however we utilised the non-commercial saddle device of Giles Brindley [4] as he showed that vibratory amplitude required to be 2.0 to 2.5 mms and frequency quite high at around 80Hz. This worked exceptionally well on paraplegic men but adverse events occurred in more than 20% (unpublished). These included hypertension with associated headaches and dysreflexia causing leg spasms and pain. We also trialled electro-ejaculation, again using devices designed by Giles Brindley, including the placement of an electrode on the fingertip of a rectal glove [5]. Beginning with experiments on himself, Brindley moved away from the rigid veterinary devices which generated a sinusoidal-wave electrical impulse of 60 Hz to the pelvic plexus at an average of 16 volts and 300 amps for up to 35 stimulations per male per session. Brindley's device stimulated the pelvic plexus at a precise point at the postero-superior aspect of the prostate gland and the controls enabled the current to be minimised (amplitude, voltage and pulse-frequencies). However, adverse reactions still occurred, including severe hypertension and autonomic hyper-reflexia, more commonly in quadriplegic males, and were most concerning to the clinical staff. None-the-less electro-ejaculation was conducted in assisted reproductive technology (ART) centres until the turn of the millennium [6] when the devices gradually became redundant. This ensued following the introduction of intra-cavernosal injections of papaverine, sometimes with the alpha-blocking agent phentolamine, and prostaglandin E1. From 23 studies, successful erections were obtained in 80% to 93% of cases with minimal side-effects [7]. A further recent development has seen trials undertaken with the orally-active phosphodiesterase type 5 (PDE5) inhibitor agents such as sildenafil. Although the reported data is minimal at this stage, trials of oral sildenafil have shown improved erections, intercourse success and increased ejaculation frequency for SCI men. The treatment appears to be well tolerated with fewer adverse reactions [8].

### **Fertility assistance for SCI men who can ejaculate**

The afore-mentioned advances have reduced the number of SCI men attending ART centres. However, the semen quality is often sub-optimal for natural conception hence some SCI men will still be referred for assisted reproduction. Where ejaculates can be achieved by one or other form of assistance, then intrauterine insemination (IUI) procedures can be undertaken, usually combined with mild ovarian stimulation of the female partner. In modern day, IUI treatment is conducted at a "gentle" level to avoid multiple pregnancies hence the pregnancy rate tends to be around 10% per treatment cycle and live births around 7 to 8%. Most ART clinics will call a halt to IUI if it has failed to generate a term pregnancy over 3 cycles, encouraging *in vitro* fertilization (IVF) where the live birth productivity rate for a single treatment cycle ranges 35%-60% for couples where the female partner is age <40 years. (Live birth productivity rate means the number of live births resulting from a single oocyte pick-up and includes all resulting embryo transfers from the fresh as well as the cryopreserved embryos). The Australia and New Zealand assisted reproduction database (ANZARD) showed that in 2016 almost 90% of ART cycles involve a single embryo transfer hence twin pregnancies occur in a low 3.8% and higher-order births do not occur nowadays. Live birth rates continue to rise with a greater shift to cryopreservation of embryos at the blastocyst stage [9]. For those SCI males requiring referral to an ART centre, there are also management options developing regarding the optimal sperm

recovery method. Clearly, where ejaculate sperm can be obtained, such samples can be prepared for IUI or IVF treatment with high success related mostly to the age of the female partner [10].

### **Fertility assistance for SCI men who cannot ejaculate**

Where the male remains an-ejaculatory, surgical sperm recovery methods will be required. We present a case report which enables us to review the various methodologies currently available, along with a specific technique which can reduce the level of invasiveness and, potentially, avoid general anaesthesia enabling sperm recovery in a day-care facility with a brief admission and minimal post-operative recovery requirement.

### **Case Description of an Ejaculatory SCI Male**

A Scottish couple were referred to PIVET from the Sir George Bed brook Spinal Unit for assistance to conceive. The wife, a project administrator, was a 30 year old nulligravida with regular menstrual cycles, no health issues and BMI 20.5 Kg/m<sup>2</sup>. Her husband was a 33 year old engineer with paraplegia. He suffered a skiing accident in Scotland 6 years prior with a resulting paraplegia from a complete T12 injury. He coped well despite his injury and requirement for wheelchair mobility. Over the period of his paraplegia, he suffered occasional urinary tract infections and required cystoscopy to remove bladder calculi on one occasion. His only other medical history was surgery as a neonate for necrotizing enterocolitis. He managed his job as an engineer quite successfully. The couple enjoyed a restricted level of sexual activity achieving transient erections but unsatisfactory intercourse and the husband was an-ejaculatory despite attempts with vibro-ejaculation and oral sildenafil. His clinical examination findings were otherwise normal and his testes were measured around 20 ml each by orchidometry. These measurements were confirmed at routine male genito-urinary ultrasound examination which showed normal renal appearances, a normal prostate and normal echogenicity of testes, with a minor hydrocele on the right but no evidence of varicoceles.

### **Surgical sperm recovery**

We explained to the couple the various methods available for sperm recovery in this situation, including our current preference for scrotal exploration under general anaesthesia enabling direct recovery by microsurgical-directed epididymal sperm aspiration (MESA) and testicular sperm extraction (TESE) procedures. We would explore sampling the epididymis, the vas and the testis in order to select the best sperm samples for IVF/ICSI. Following consent this was undertaken in PIVET's day-care theatre. Exploration was undertaken via a midline raphe incision enabling access to both sides, however only the left side was explored as abundant motile spermatozoa were recovered. The testicular features and other anatomical aspects were noted to be completely normal, with a well-defined vas. The epididymis was not distended. We explored 3 areas applying micro-surgical techniques using the Leica Wild-Heerbrugg M690 operating microscope for optimal visualization and fine suturing which was applied to the epididymis and vas repair sites (Figure 1).

Sperm samples were recovered from three sites:

1. Vasal flush - Retrieved numerous motile sperm; 10 straws cryopreserved
2. MESA sites in caput - Too few spermatozoa identified; nil straws cryopreserved
3. Testicular - Modest numbers of sperm retrieved; one straw cryopreserved

## Surgical sperm recovery techniques

**Vasal flush:** The technique for Vasal Flush involved dissecting out a segment of the vas and separating away the fascial coverings. Thereafter, under binocular microscope vision X16, the vas was incised hemi-spherically to expose the internal canal. A 24 gauge (0.7 x 19 mm) IV cannula was threaded into the proximal vas (towards the testis) attached to a 2 ml syringe filled with culture medium (Quinn's Advantage containing Hepes buffer; Origio Australasia; with added human serum albumin and heparin) (Figure 2). A firm pressure was applied to the plunger, keeping the vas well gripped around the cannula, and the pressure maintained for 60 seconds to enable a syringing action of the convoluted portion of the vas along with the distal, cauda epididymis which was seen to visibly contract (Figure 3). Thereafter the plunger was relaxed and aspirated to draw up the visibly milky semen into the syringe. The embryologist identified abundant motile spermatozoa at the microscope bench assembled within the operating theatre (Figure 4). Thereafter X3 sutures of 8/0 nylon were placed under microsurgical vision X20.

**MESA:** The technique of MESA involved micro-incision using an ophthalmic scalpel into 3 separate vasa efferential ducts at the

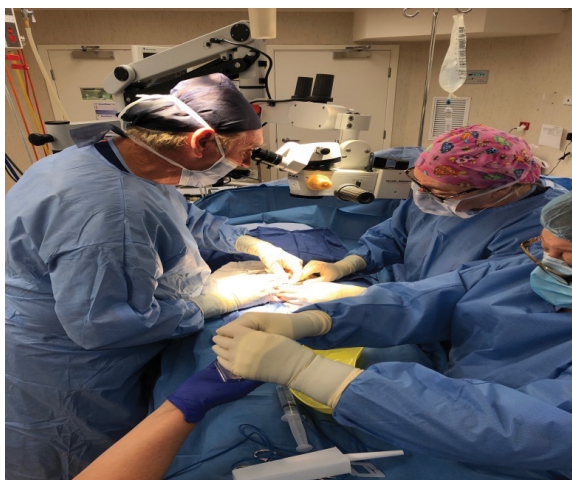

Figure 1: Microsurgical set-up in the day-theatre for open scrotal surgery.

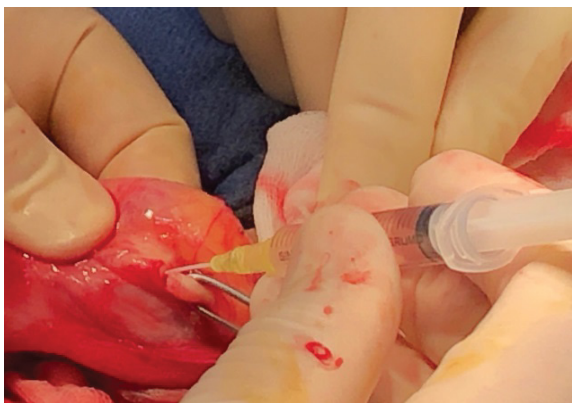

Figure 2: Cannulation of the vas deferens by a 24 g iv cannula enabling a forced retro-flush of the proximal vas (convoluted segment) and cauda epididymis. This picture is taken during an open scrotal dissection but the vas can be easily exposed with a minimal access scrotal incision. Closure of the vas is best performed with microsurgery.

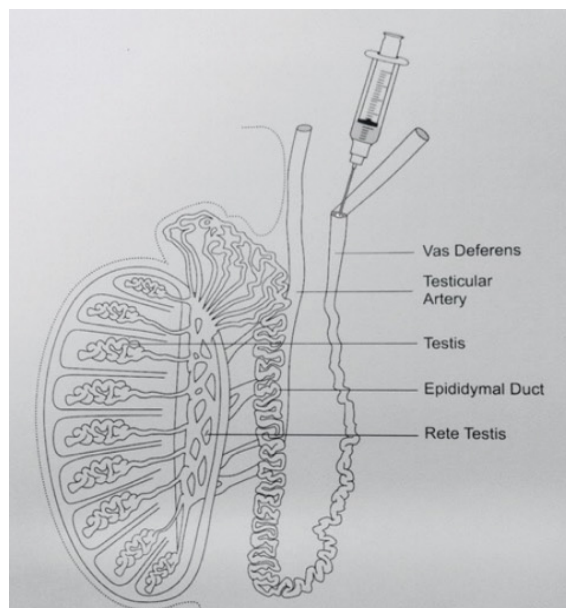


Figure 3: Diagram of vasal flush procedure as drawn by co-author Dr Anne Jequier. The cauda epididymis extends into the convoluted portion of the vas, gradually merging into the straight vas deferens.

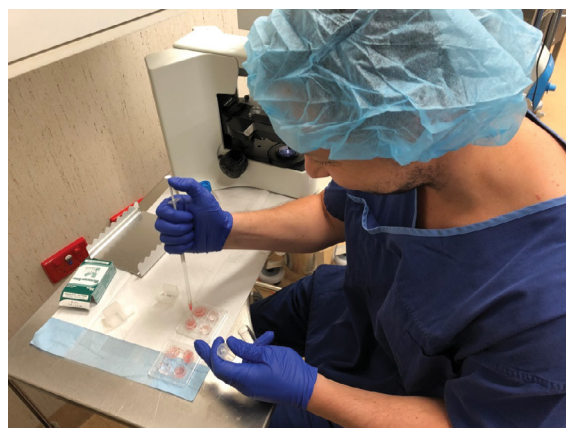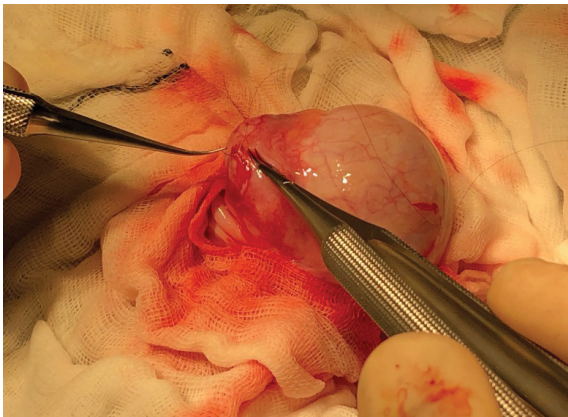


Figure 4: Embryologist sited in the theatre to undertake sperm search from the various specimens derived from MESA, vasal flush and testicular biopsy.

caput epididymis under microsurgical vision X16 with aspiration of light milky fluid in very small samples. These were transferred to a 4-well Nunc dish containing the Hepes-buffered culture medium for the embryologist to identify and collect the samples. Thereafter the incisions were sutured with interrupted 8/0 nylon under magnification x20 (Figure 5).

**TESA and TESE:** The testicular samples were recovered as part of a small testicular biopsy under normal vision and the sample placed in a Nunc dish containing the Hepes-buffered medium. As the embryologist identified motile spermatozoa, no further exploration of the testis was performed; however, in other cases of non-obstructive azoospermia, the approach is via a Schlegal butterfly incision with microsurgical identification/ excision of focal areas comprising swollen spermatogenic tubules; so-called TESE [11]. After separating a small part of the testicular biopsy for histological evaluation, the remainder





**Figure 5:** Microsurgical closure of MESA sites using 8/0 Nylon. Similar suturing is applied to the hemisected vas deferens. Finer suturing with 10/0 Nylon is used for reconstructive surgeries e.g. vazo-epididymostomy.

was carefully disaggregated through a tea-strainer to maximise the recovery of motile spermatozoa.

The scrotum was closed in layers after replacing the testis into the tunica vaginalis sac, closed with a running 5/0 polydioxanone (PDS) suture. The Dartos layer was similarly closed and interrupted sutures of 5/0 PDS were used to close the skin. Such sutures would dissolve over a 7 to 10 day period. Antibiotic cover was given with ceftriaxone 2 gram IV.

All sperm samples were cryopreserved in glycerol-containing medium within 0.25 ml straws suspended over liquid nitrogen vapour for 5 minutes, prior to placement into goblets and plunged into the liquid nitrogen at -196°C for long-term cryostorage.

Histology on the testicular biopsy was reported as “spermatogenesis is present in almost all tubules. There is some degree of interstitial scarring and in many of the tubules there is a degree of sloughing of immature forms”.

### IVF and pregnancy

IVF was conducted the following month utilising an antagonist cycle for the wife who had an antral follicle count showing 10-12 small antral follicles in each ovary (categorised A according to PIVET FSH dosing algorithm and a serum anti-mullerian hormone level of 26.9 pmol/L (consistent with the A categorisation for ovarian reserve) [12]. The rFSH dosage was 100 IU daily and Trigger was GnRH agonist on Day-12 of the cycle in accordance with PIVET protocol when E2 level is >12,000 pmol/L and >12 follicles arise. Oocyte pick-up was performed 38 hours post-Trigger but only 5 oocytes were recovered as the advanced follicles had already ovulated. Approximately 300 ml slightly blood-stained follicular fluid was also aspirated from the Pouch of Douglas; evidence of premature ovulation but no oocytes were detected, the presumption being that they had already entered the fallopian tubes which were known to be normal as bilateral patency had been demonstrated on a HyCoSy evaluation the previous month.

Of the 5 oocytes recovered, 4 fertilised applying ICSI from 1 straw thawed from the Vasal Flush samples. All oocytes fertilised and 4 progressed to Day-3, being 1 X 6 cell and 3 X 8 cells with good to excellent scoring grades. One of the highest-grade embryos was transferred at the cleavage-stage and the luteal phase was managed with progesterone pessaries. The remaining embryos were cultured 3 more days when a single Day 6 Blastocyst Graded 4AB was vitrified [13].

Unfortunately, pregnancy did not ensue in that treatment cycle but subsequently, 15-months later, the couple returned to have the vitrified embryo transferred. This was conducted according to our published FET/HRT regimen. The mid luteal progesterone was 42 nmol/L, which is below our desirable level of 60 nmol/L, hence the progesterone pessaries were increased showing a higher level of 95 nmol/L at the time of the pregnancy test which, this time, was happily positive [14].

Pleasingly the pregnancy advanced normally and the first trimester screening test was normal. At 40 weeks and 4 days a healthy male infant was delivered with birth weight 3600 g by spontaneous vaginal delivery. He is now aged almost 4 years and we received a picture of him playing with his proud father, which prompted us to document this case-report.

A further IVF procedure was conducted after this birth. We moderated the rFSH dosage and timed the Trigger for 36 hours on this occasion. From 13 follicles punctured 12 oocytes were recovered and 9 MII oocytes had ICSI again using a second straw from the 10 cryopreserved Vasal flush samples. At Day-3 eight cleavage-stage embryos had developed of which 3 developed to suitable blastocysts for Vitrification. That cycle was conducted as an elective freeze-all pending a scheduled trip back to the UK; hence no embryo transfer procedure occurred. Two further pregnancies have ensued following single embryo transfers of 2 of the blastocysts, however, both eventuated in failed pregnancies around 9-weeks' gestation. One of these had cytogenetic testing of the product of conception showing a normal 46XX chromosomal configuration; the other resulted in a complete miscarriage without curettage.

### Ethical Issues

PIVET Medical Centre is accredited for IVF-related services by the Reproductive Technology Accreditation Committee 20180501 Deed of Agreement current to May 2019. Bellberry Human Research Ethics Committee provides oversight for clinical and surgical procedures including patient information documentation for informed consent, P1009a. Extension of approval for reporting retrospective data is provided from Curtin University Ethics Committee last updated 14 April 2015 for review 23 August 2019: Approval Number RD-25-10.

### Discussion

Surgical sperm retrievals have become an established part of IVF practice, beginning in 1985, those early cases being performed on men with obstructive azoospermia (OA), mostly post-vasectomy but also congenital bilateral absence of the vas deferens (CBAVD), and obstructions higher in the male tract e.g. post-inflammatory blockage of the ejaculatory ducts or from compression due to a Prostatic Utricle cyst [15,16]. Subsequently, cases of non-obstructive azoospermia (NOA) have been explored and successful sperm retrieval is described in 30% to 50% of cases. These have included cases of spermatogenic failure, underlying germinal aplasia, germinal hypoplasia (collectively Sertoli cell-only syndromes), sperm maturational arrest and a range of unexplained causes, some possibly due to environmental toxins, occupational hazards such as heat, chemical exposure and perhaps combined factors such as varicocele/obesity and prolonged sitting [17,18]. A recent Editorial examines the aspects of open microsurgical approaches versus percutaneous needling for sperm retrievals, as well as the carrier used for cryopreservation of samples [19].

The Case Report presented here relates to a man with aspermia rather than azoospermia. His problem is that of an-ejaculatory aspermia and it is of some interest to consider the history leading to our application of a surgical (microsurgical) approach to sperm recovery. Each of the authors has a long history (20-40 years) of undertaking

sperm retrievals from men with spinal injury. These have included vibro-ejaculation with various devices, electro-ejaculation with a couple of devices and using prostaglandin E2 intra-penile injections to create a sustained erection for masturbatory attempts. Suffice it to conclude we have seen various complications including hyper-reflexia, malignant hypertension and bowel burns arise from these methods and no longer favour them. Furthermore, we now believe that sperm collection which by-passes the bladder, prostate, seminal vesicles and urethra in such men is far better, ensuring uncontaminated samples are retrieved and the problems of infection and reactive oxygen species generation is minimized [20]. Therefore, surgical recovery from the testis, epididymis and vas are nowadays the preferred areas for recovery where the SCI male remains infertile. Such sperm is precious and best utilized in an IVF procedure, particularly where there are co-existent female factors, including advanced female age >35 years.

However, the matter is not as simple as it might first appear. MESA is a well-established procedure with very high success for men with OA. However, men who have neither OA nor NOA (i.e., normal spermatogenesis) will not have sperm building up in the epididymis. Such was revealed in our Case Report. Co-author AMJ showed quite elegantly in her post mortem studies on young, fit men suffering sudden traumatic death following motorcycle or similar accidents, do not have sperm in the caput or corpus of the epididymis [21]. The transit for normal, healthy men is very rapid. However, we do believe that sperm are stored in the convoluted portion of the vas adjacent to the cauda epididymis, and that is why our Vasal flush technique retrieved abundant numbers of good quality, useful sperm as shown by the IVF outcomes in our couple.

Of course, the easier target might be seen to be the testis; certainly, we obtained sperm from that site and we are aware that testicular sperm can be used in IVF quite successfully. However, we agree with Sherman Silber's group that sperm which have completed maturation in the testis and travelled on from the rete testis into the efferent ducts and then to distant parts i.e. the epididymis and thereafter the Vas, will be the best for fertilization and improving the generation of healthy children. Such offspring should be free from the epigenetic problems which are reported to be higher following ICSI, the process required to achieve satisfactory rates of fertilization in IVF programs when using surgically-retrieved sperm [22,23].

Following the findings in this Case Report, we have started to explore Vasal Flush as an independent, minimally invasive procedure, under local anaesthesia or spinal block. It can be performed without scrotal exploration, in a procedure not much more complex than a Vasectomy i.e. the vas can be exposed via a small skin incision and the duct cannulated as described in the Case Report. If abundant sperm are retrieved there will be no need to consider exploration of the testis, although if sperm are not retrieved, one must be prepared for such exploration along with testis biopsy for diagnostic purpose. This means the theatre environment with the potential for iv sedation or general anaesthetic facilities, along with surgical equipment and microscope plus embryology facilities are optimal requirements. Although the skin incision is small, requiring only one or 2 PDS sutures, the vas should be reconstituted properly; preferably with 2-3 fine sutures placed under micro-surgical vision.

We have also found that the indications for Vasal Flush are extending beyond the spinal-injured male, but also into other causes for an ejaculation including men with neurogenic causes (Diabetes mellitus, Parkinson's disease, multiple sclerosis and motor neurone disorders), psychogenic causation as well as an-ejaculatory transgender males who are seeking sperm storage for potential future use.

Also, some cases of retrograde ejaculation should be considered for the Vasal Flush technique, as well as those men debilitated from cancer wishing to have sperm storage prior to definitive treatments [24].

## References

1. Yovich JL, Keane KN (2017) Assessing the male in fertility clinics-men undervalued undermanaged and undertreated. *Transl Androl Urol* 6: 624-628.
2. Dimitriadis F, Karakitsios K, Tsounapi P, Tsambalis S, Loutradis D, et al. (2010) Erectile function and male reproduction in men with spinal cord injury. *Andrologia* 42: 139-165.
3. Ibrahim E, Lynne CM, Brackett NL (2016) Male fertility following spinal cord injury: an update. *Andrology* 4: 13-26.
4. Brindley GS (1981) Reflex ejaculation under vibratory stimulation in paraplegic men. *Paraplegia* 19: 299-302.
5. Brindley GS (1981) Electroejaculation: its techniques, neurological implications and uses. *J Neurol Neuro Psychiatr* 44: 9-18.
6. Rainsbury. Eds: Peter R Brinsden and Paul A Rainsbury. Parthenon P (1992) The treatment of male factor infertility due to sexual dysfunction In A textbook of in vitro fertilization and assisted reproduction Publishing Group, Camforth Lancashire UK. 1: 345-359.
7. Chochina L, Naudet F, Chéhensse C, Manunta A, Damphousse M, et al. (2016) Intracavernous injections in spinal cord injured men with erectile dysfunction asystematic review and meta-analysis. *Sex Med Rev* 4: 257-269
8. Ohl DA, Carlsson M, Stecher VJ, Rippon GA (2017) Efficacy and Safety of Sildenafil in men with sexual dysfunction and spinal cord injury. *Sex Med Rev* 5: 521-528.
9. Fitzgerald O, Paul RC, Harris K, Chambers GM (2018) Assisted reproductive technology in Australia and New Zealand 2016. National Perinatal Epidemiology and Statistics Unit University of New South Wales Sydney p: 83.
10. Mariappen U, Keane KN, Hinchliffe PM, Dhaliwal SS, Yovich JL (2018) The influence of male age and semen parameters on clinical pregnancy and live birth outcomes from IVF *Reprod Biol*: <https://doi.org/10.1016/j.repbio.2018.11.003>
11. Schlegel PN (1999) Testicular sperm extraction: microdissection improves sperm yield with minimal tissue excision. *Hum Reprod* 14: 131-135.
12. Yovich JL, Alsbjerg B, Hinchliffe P, Keane KN (2016) PIVET rFSH dosing algorithms for individualised controlled ovarian stimulation enables optimised pregnancy productivity rates and avoidance of ovarian hyperstimulation syndrome. *Drug Design, Development & Therapy* 10: 2561-2573.
13. Gardner DK, Schoolcraft WB (1999) In vitro culture of human blastocysts In Robert Jansen R and David Mortimer (eds). *Toward Reproductive Certainty: Fertility and Genetics Beyond* London UK: Parthenon Publishing Pp: 378-388.
14. Yovich JL, Conceicao JL, Stanger JD, Hinchliffe PM, Keane KN (2015) Mid-luteal serum progesterone concentrations govern implantation rates for frozen embryo transfers conducted under hormone replacement. *Reprod BioMed Online* 31: 180-191.
15. Temple SPD, Southwick GJ, Yates CA, Trounson AO, de KDM (1985) Human pregnancy by in vitro fertilization (IVF) using sperm aspirated from the epididymis. *J In Vitro Fer Embryo Trans* 2: 119-122.
16. Jequier AM, Cummins JM, Gearon C, Apted SL, Yovich JM, et al. (1990) A pregnancy achieved using sperm from the epididymal caput in idiopathic obstructive azoospermia. *Fertil & Steril* 53: 1104-1105.
17. Jequier AM (1995) Clinical disorders affecting sperm function. In *Gametes - The spermatozoon Cambridge Review in Human Repro* (Eds: JG Grudzinskas & JL Yovich) Cambridge University Press, Cambridge, UK. 316: 175-191.
18. Jequier AM (2011) Male Infertility: a clinical guide. Cambridge Uni Press Second Edition pp264 Chapter 17 Disorders of Ejaculation and Chapter 18: Spinal cord injury and the infertility it causes. Pp: 153-172.
19. Blecher GA, Katz DJ (2018) Evaluation and management of an infertile male who is found to have azoospermia. *Brit J Urol Int* in Press.
20. Yovich JL, Esteves SC (2018) Storage of sperm samples from males with azoospermia. *Repro BioMedicine Online* 37: 509-510.
21. Jequier AM, Yovich SJ, Pemberton R, Cohen R, Yovich JL (2013) Cellular Damage to the human caput epididymis resulting from vasal obstruction. *Androl Gynaecol Curr Res* 1: 3.

- 
22. Van WM, Barbey N, Meissner A, Repping S, Silber SJ (2015) Live birth rates after MESA or TESE in men with obstructive azoospermia: is there a difference? *Hum Reprod* 30: 761-766.
23. Hansen M, Greenop KR, Bourke J, Baynam G, hart RJ, et al. (2018) Intellectual disability in children conceived using assisted reproductive technology. *Pediatrics* 142: e20181269.
24. Katz DJ, Kolon TF, Feldman DR, Mulhall JP (2013) Fertility preservation strategies for male patients with cancer. *Nature Reviews Urology* 10: 463-472.